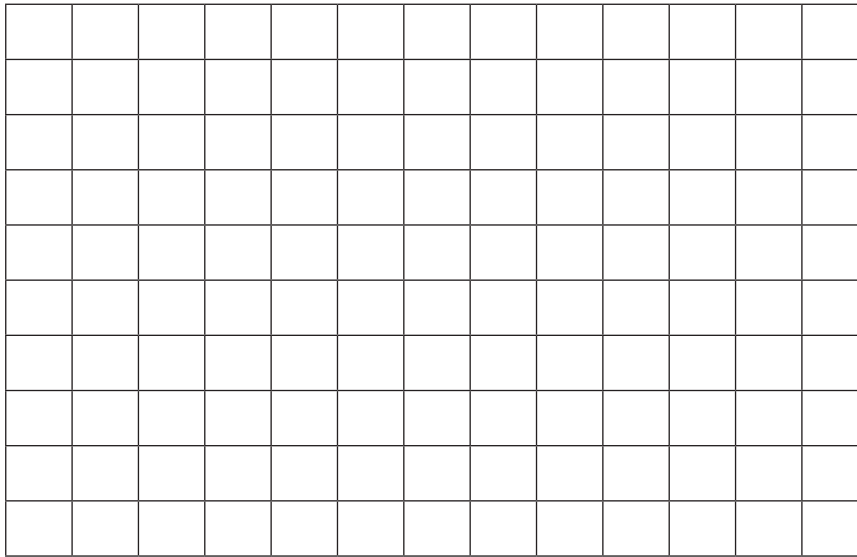


Observations

[illegible][illegible]

Sketch of Transverse Cross Section



Post-Lab Questions *(refer to sketches to answer the following questions)*

1. Using a blue colored pencil, color in the squares in the *Gingerbread man in anatomical position* diagram to show the portions that were diagrammed in the *medial* cross section.
2. Using an orange colored pencil, color in the squares *Gingerbread man in anatomical position* diagram to show the portions that were diagrammed in the *transverse* cross section.
3. In original form, which of the identified organs of the gingerbread man is most superior?
4. In the medial cross section, which organ is the most anterior organ?
5. Identify the organ that was viewed in the transverse cross section.
6. If a medical professional wanted to study the structural relationship between the spine, esophagus and neck, which body plane would be the most appropriate?
7. Explain the importance of anatomical and relative position to medical professionals.